



Cone-beam computed tomography study of tooth root and canal morphology of permanent molars in a Serbian population

Analiza morfologije korenova i kanala korenova stalnih molara primenom kompjuterizovane tomografije konusnog zraka u populaciji Srbije

Milica Popović, Suzana Živanović, Tamara Vučićević, Miona Grujović,
Miloš Papić

University of Kragujevac, Faculty of Medical Sciences, Department of Dentistry,
Kragujevac, Serbia

Abstract

Background/Aim. For successful endodontic therapy, it is necessary to know root morphology. Therefore, the aim of our study was to analyze root canal morphology and root canal length of permanent molars in a Serbian population, using cone-beam computed tomography (CBCT). **Methods.** The study included a total of 305 maxillary molars, and 280 mandibular molars receiving cone-beam computed tomography examination and determined root numbers, canal morphology according to Vertucci classification, and canal lengths. Results were correlated with sex and tooth location in the jaw. **Results.** The mesiobuccal roots of first maxillary molars showed Vertucci type I in 45.7%, followed by type II in 29% of cases. For the second molar, Vertucci type I was found in 60.5% of cases in mesiobuccal canals. Palatal and distobuccal canals mostly presented Vertucci type I configuration. The mesial roots of mandibular molars had the highest frequency of two canals with Vertucci type IV as the most frequent for the first molar, and Vertucci type II for the second molar. Distal roots most commonly had one canal in both molars. Palatal canal length was the highest in maxillary first molars, with the mean value of 20.62 mm, while in second molars, the highest length value was for the mesiobuccal canal (20.09 mm). In both mandibular molars the mesial root canal was the longest one. Differences were found according to sex and tooth location in the jaw. **Conclusion.** Mesiobuccal roots of maxillary first molars had two canals; it was more frequently compared to second molars. Mesial roots of mandibular molars showed same frequency of two canals, and diversity in Vertucci types. Male patients tended to have higher complexity of root canal morphology compared to that of females. CBCT can improve understanding of the root canal morphology.

Key words:

tooth root; molar; cone-beam computed tomography; serbia.

Apstrakt

Uvod/Cilj. Za uspešnu endodontsku terapiju neophodno je poznavanje morfologije kanala korena zuba. Stoga je cilj naše studije bio da analiziramo morfologiju kanala i dužinu kanala korenova stalnih molara u populaciji Srbije, koristeći kompjuterizovanu tomografiju konusnog zraka (*cone-beam computed tomography* – CBCT). **Metode.** Studijom je obuhvaćeno ukupno 305 gornjih i 280 donjih molara snimljenih CBCT-om na kojima su analizirani broj korenova, morfologija kanala prema Vertučijevoj klasifikaciji i dužina kanala korenova. Procenjena je povezanost dobijenih rezultata sa polom i lokacijom zuba u vilici. **Rezultati.** Meziobukalni korenovi gornjeg prvog molara imali su tip I po Vertučiju u 45,7%, a tip II u 29% slučajeva. Kod gornjeg drugog molara, Vertučići tip I pronađen je u 60,5% slučajeva u meziobukalnim kanalima. Palatinalni i distobukalni kanali su uglavnom imali konfiguraciju kanala tipa I po Vertučiju. Mezijalni korenovi donjih molara najčešće su imali dva kanala, sa najvećom zastupljenošću Vertučići tipa IV u prvom, a Vertučići tipa II u drugom molaru. Distalni korenovi najčešće su imali jedan kanal u oba molara. Dužina palatinalnog kanala bila je najveća kod gornjih prvih molara, sa srednjom vrednošću od 20,26 mm, dok je kod drugih molara najveća bila vrednost meziobukalnih kanala (20,09 mm). Kod oba donja molara najduži su bili mezijalni kanali. Razlike su pronađene u odnosu na pol i stranu zuba u vilici. **Zaključak.** Meziobukalni korenovi gornjih prvih molara imali su češće dva kanala u poređenju sa drugim molarima. Mezijalni korenovi donjih molara pokazali su sličnu učestalost dva kanala i ranolikost u tipovima prema Vertučijevoj kasifikaciji. Kod osoba muškog pola zapažena je veća učestalost kompleksne morfologije kanala korenova u poređenju sa osobama ženskog pola. CBCT može poboljšati razumevanje morfologije kanala korenova.

Ključne reči:

zub, korenski kanal; molari; tomografija, kompjuterizovana konusna; srbija.

Introduction

The aim of endodontic therapy is to eliminate the inflamed tissue or infection from the root canal of the teeth, through mechanical shaping and chemical irrigation, followed by adequate obturation of the root canal¹. In order to achieve a favourable outcome of endodontic therapy, knowledge of the root canal morphology is necessary². Endodontic treatment of molar teeth presents a challenge due to the position of teeth in the jaw, the crown's morphological characteristics, the large number of roots and their complex canal system³. The first permanent molars are the first erupted teeth, and for this reason, they are often affected by caries, which can lead to pulpitis and a need for their endodontic treatment. In a number of cases, permanent molars are extracted, mostly due to the unsuccessful endodontic treatment². The main reason for the failure in endodontic therapy is leaving the root canal untreated due to its complexity^{1,3}. In addition, it is necessary to adequately determine the root canal length. Overtreating the canal or leaving it untreated, prior to the cementodentinal junction, can also be the cause of failure in endodontic therapy. Therefore it is important to have an overview of the expected, i.e. the average length of the root canal⁴⁻⁶.

It has been shown that the number of roots and root canals is different among populations, probably because these differences are genetically predetermined⁷. In the most cases, maxillary molars have three roots and three or four root canals. The frequency of the second mesiobuccal canal is around 50%⁸. Unlike the mesiobuccal canal, the morphology of the distobuccal and palatal canals is quite simpler, the distobuccal root has one canal in about 90% of cases, and palatal root in 99% of cases^{7,9}. Mandibular molars have less complicated canal morphology than maxillary molars. Two roots are present in more than 87% of cases, and only 13% of mandibular molars have three roots^{1,10}. Three roots are more present in Chinese, Native American, and Eskimo populations, while slightly simpler morphology is present in Caucasians⁷. The mesial root has two canals in 94%, while three canals are present in a small percentage. Differences in root canal morphology are claimed to be related to ethnicity as one root canal occurs more frequently in Caucasians⁷.

Morphological variations in the number of roots and canals are evaluated by various methods, and therefore the results vary depending on applied methods, as well as ethnicity, sex, age and side of the jaw^{11,12}.

Digital dental radiography is required in endodontic therapy. Cone-beam computed tomography (CBCT) is a radiographic method that offers many benefits and possibilities, but it should not be routinely performed in endodontics, due to higher exposures to radiation. Mostly, patients have a CBCT scan taken for other reasons (interventions in oral surgery, orthodontics, and prosthodontics) and therefore can be used for endodontic evaluation as well^{6,7}.

According to our knowledge, there are few studies that describe the root and root canal morphology in a Serbian population. The aim of this study was to evaluate the number of roots and root canal morphology, including canal length, of maxillary and mandibular first and second molars and

variations between sexes and side of the jaw. This study is part of a major research of the root morphology, which we conducted at the Faculty of Medical Sciences, University of Kragujevac, Serbia^{13,14}.

Methods

The research protocol was approved by the Ethics Committee of the Faculty of Medical Sciences, University of Kragujevac, Serbia, and it was conducted in compliance with the Helsinki Declaration and Guidelines for Good Clinical Practice.

Sample

The total study sample included images of 585 teeth, obtained from CBCT scans out of 192 patients from a pre-existing database. All CBCT images were made in Radiology Department, Faculty of Medical Sciences, University of Kragujevac, between October 25th, 2014 and October 25th, 2017. The scans were obtained using Orthophos XG 3D device (Sirona Dental Systems GmbH, Bensheim, Germany), with three-dimensional settings for recording, VOL1 or VOL1 HD, and a voxel size of 160 μm ; the layer thickness was 0.16 mm with large Field of view (FOV). The reasons for CBCT scanning were different (prosthetic, surgical, orthodontic and endodontic).

The main image's inclusion criterion was the existence of at least one molar in the maxilla or mandible. Other inclusion criteria were following: tooth is fully visible; has completed root growth; has no radiographically visible periapical lesion; has no radiographically visible external or internal root resorption; is not treated endodontically and has no prosthetic restoration.

Radiography and measurements

CBCT images were analyzed using a software GALAXIS v 1.9.4 (Sirona Dental Systems GmbH, Bensheim, Germany), in the axial, sagittal, and coronal sections. Observations were conducted at Philips LED monitor, sized 23-inch, with a resolution of 1,920 \times 1,080 pixels, in a room with dim lighting. Brightness and contrast were adjusted using a software program.

Teeth were classified into groups (maxillary first molar, maxillary second molar, mandibular first molar and mandibular second molar), and the following parameters were observed: the number of roots per tooth; the number of root canals per root; the root canal configuration according to Vertucci classification¹ (Figure 1 and Table 1); root canal lengths; position of the tooth – left or right side of the jaw; patient's sex.

Canal length was determined using a 3D approach as proposed by Tchorz et al.⁵. The length of the canal was considered to be the distance from the tip of the reference cusp to the apical foramen. The measurements were performed in the sagittal and axial plane, and the length was obtained by adding the distance between the reference

points. Since molars have root curvatures in many cases, they were marked as additional reference points located on

the axial cross-section and by adding the distances between them, the lengths of the molar root canals were obtained.

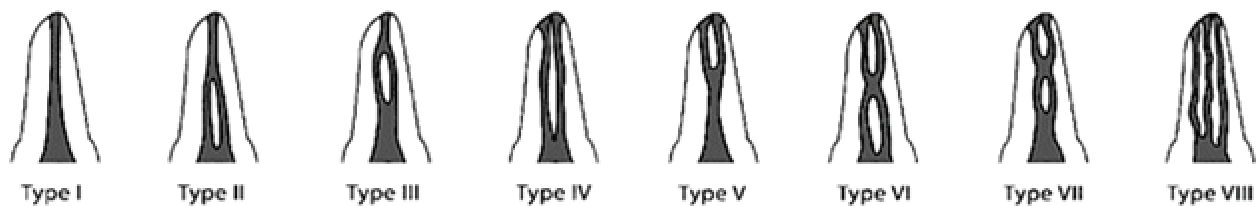


Fig. 1 – Diagrammatic representation of Vertucci root canal configurations.

Table 1

Descriptions of different root canal morphological types according to Vertucci

Type	Description
I	A single canal appears from the pulp chamber to the apex.
II	Two separate canals leave the pulp chamber but merge into one to the apex.
III	A single canal leaves the pulp chamber, divides into two within the root, and then merges to the apex.
IV	Two distinctly separate canals are present from the pulp chamber to the apex.
V	A single canal leaves the pulp chamber but divides into two with two apical foramina.
VI	Two separate canals leave the pulp chamber, join at the midpoint, and then divide again into separate canals with two separate apical foramina.
VII	One canal leaves the pulp chamber, divides and then rejoins within the root, and finally redivides into two separate canals with two separate apical foramina.
VIII	Three separate and distinct canals begin from the pulp chamber to the root apex.

Statistics

Statistical data were analyzed using a commercial software package for statistics SPSS v 20.0 (SPSS Inc., Chicago, IL, USA). The frequencies and correlations of the values of the number of roots and the root canals and the root canal configuration according to Vertucci's classification were analyzed between the sexes and the side of the jaw on which the tooth is located using the χ^2 test and Fisher's exact test. Differences in the length of the root canal between the sexes and the jaw sides were analyzed using the Mann-Whitney *U*-test. The values of categorical variables are shown as percentages and numerical variables as the mean value and standard deviation (mean value \pm SD). The obtained *p* value less than 0.05 was considered as statistically significant.

Results

In this study, mandibular and maxillary first and second molars were examined. We analyzed the number of roots and

canals, root canal length, and canal morphology according to Vertucci classification.

Maxillary molars – number of roots

A total of 305 maxillary molars were examined in this study.

The results for the number of roots are shown in Table 2. Of the total, 138 were maxillary first molars.

Within this subgroup, teeth with three roots were the most frequent finding (99.3%), while only one tooth was found with two roots (0.7%).

Within maxillary second molars, three roots were found in the majority of cases (90.4%), followed by two roots (5.4%), and one root (3.6%).

Four roots were found in only one case (0.6%).

There was a statistically significant difference in the number of roots according to sex ($p = 0.008$) – one and two roots were more common in women (8.4%) than in men (1.2%).

Table 2

Number of roots of maxillary and mandibular molars

Tooth	Number (%) of roots			
	1 root	2 roots	3 roots	4 roots
Maxillary first molar	0 (0.0)	1 (0.7)	137 (99.3)	0 (0.0)
Maxillary second molar	6 (3.6)	9 (5.4)	151 (90.4)	1 (0.6)
Mandibular first molar	0 (0.0)	118 (100)	0 (0.0)	0 (0.0)
Mandibular second molar	4 (2.5)	158 (97.5)	0 (0.0)	0 (0.0)

Number and morphology of root canals

Among distobuccal and palatal canals of maxillary molars, a single root canal, or Vertucci type I (100%), was found in the palatal root of maxillary first and second molars. Vertucci type I was the most frequent (97.1%) in distobuccal roots maxillary first molars, and the distobuccal roots of the maxillary second molars had one canal in all cases (100%).

The number of canals in the mesiobuccal roots of maxillary molars is shown in Table 3. The second mesiobuccal canal was present in 54.3% cases in the maxillary first molars, and 39.5% cases in the maxillary second molars (Figure 2). All types of Vertucci classification other than the

type I were considered as the presence of second mesiobuccal root canal. There was a statistically significant difference in the number of root canals according to sex for the maxillary first molar – one canal was more frequent in females (71.4%) than in males (28.6%), while two canals were more frequent in men (60.0%) than in women (40.0%). Vertucci classification of the mesiobuccal root canals of maxillary molars is shown in Table 4. There was a statistically significant difference in relation to sex ($p = 0.001$), where type I was more frequent in women (71.4%), while type II (67.5%) was more frequent in men. In the maxillary second molar, there was no statistically significant difference in the root canal configuration between the sexes ($p = 0.055$).

Table 3

Number of canals in mesiobuccal roots of maxillary molars according to sex

Tooth	Number of root canals	Sex, n (%)		Total	<i>p</i>
		male	female		
Maxillary first molar	1	18 (28.6)	45 (71.4)	63 (100)	0.003*
	2	45 (60.0)	30 (40.0)	75 (100)	
	Total	63	75	138	
Maxillary second molar	1	47 (46.5)	54 (53.5)	101 (100)	0.269
	2	37 (56.1)	29 (43.9)	66 (100)	
	Total	59	108	167	

*Statistically significant difference using the Fisher's Exact Test.

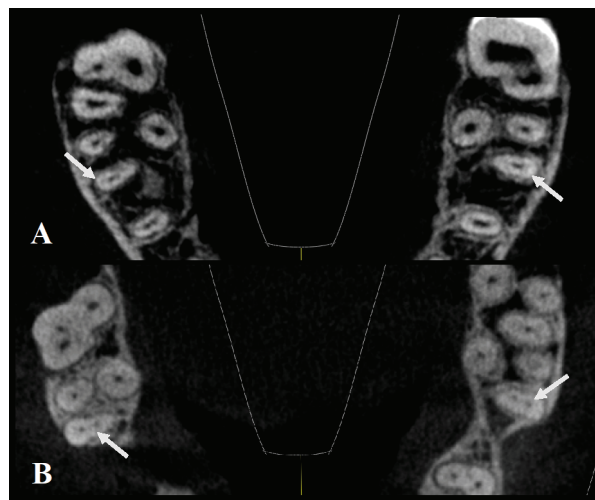


Fig. 2 – Axial cross-sections of the maxilla, arrows showing maxillary first molars with one canal (A), and two canals (B) bilaterally in mesiobuccal roots.

Table 4

Distribution of Vertucci classification in mesiobuccal roots of maxillary molars according to sex

Tooth	Vertucci classification, n (%)						Total	<i>p</i>
	type I	type II	type III	type IV	type V	type VII		
Maxillary first molar								
Sex								
male	18 (28.6)	27 (67.5)	8 (66.7)	4 (33.3)	6 (54.5)	0 (0.0)	63	0.001*
female	45 (71.4)	13 (32.5)	4 (33.3)	8 (66.7)	5 (45.5)	0 (0.0)	75	
Total	63 (45.7)	40 (29.0)	12 (8.7)	12 (8.7)	11 (8.0)	0 (0.0)	138 (100)	
Maxillary second molar								
Sex								
male	47 (46.5)	22 (62.9)	4 (66.7)	4 (28.6)	7 (77.8)	0 (0.0)	84	0.055
female	54 (53.5)	13 (37.1)	2 (33.3)	10 (71.4)	2 (22.2)	2 (100)	83	
Total	101 (60.5)	35 (21.0)	6 (3.6)	14 (8.4)	9 (5.4)	2 (1.2)	167 (100)	

*Statistically significant difference using the Pearson χ^2 -test.

Mandibular molars – number of roots

In the analysis of 280 mandibular molars on the CBCT, all mandibular first molars were two-rooted (100%), while among mandibular second molars, two roots were present in the majority of cases (Table 2). There was no statistically significant difference in relation to sex or jaw side.

Number and morphology of root canals

Of examined 118 mandibular first molars, the mesial root had two root canals in 94.9%, and one canal in 5.1% of cases. The distal root had one root canal in 89.8%, while two root canals were present in 10.2% of cases. Out of total 162

mandibular second molars, the mesial root had two canals in 85.2%, and one canal in 14.8% cases. One canal was the most prevalent in the distal root of the mandibular second molar (98.7%), while two canals were founded in 1.3% of cases (Figure 3).

Analysis of the distal root canal morphology of the mandibular first molar showed the highest frequency of Vertucci type I (89.8%), followed by Vertucci type II and type III (5.1% both). In the distal root of the mandibular second molar, the most common was Vertucci type I (98.7%), followed by Vertucci type II (1.3%). The differences between sexes or jaw sides, in canal configurations of the mesial root of the mandibular first and second molars, were not statistically significant (Table 5).

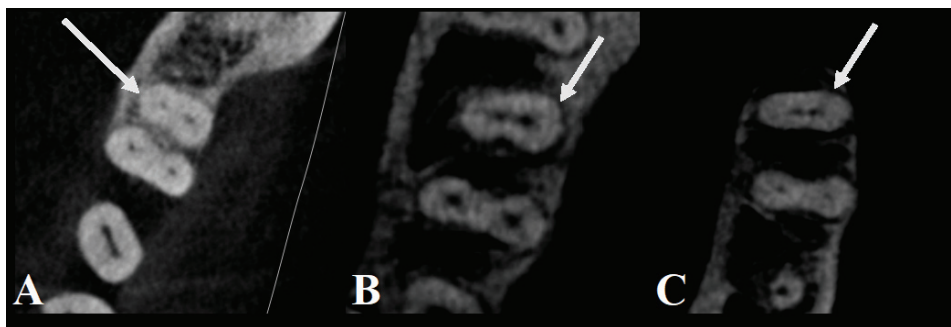


Fig. 3 – Axial cross-sections of mandibular first (A, B) and second (C) molars, arrows showing two canals in distal roots.

Table 5

Distribution of Vertucci classification in mesial roots of mandibular molars according to sex

Tooth	Vertucci classification, n (%)				Total	p
	Type I	Type II	Type III	Type IV		
Mandibular first molar						
Sex						
male	4 (66.7)	26 (61.9)	0 (0.0)	28 (40.0)	58	0.055
female	2 (33.3)	16 (38.1)	0 (0.0)	42 (60.0)	60	
Total	6 (5.1)	42 (35.6)	0 (0.0)	70 (59.3)	118 (100)	
Mandibular second molar						
Sex						
male	14 (58.3)	42 (63.6)	4 (40.0)	36 (58.1)	96	0.551
female	10 (41.7)	24 (36.4)	6 (60.0)	26 (41.9)	66	
Total	24 (14.8)	66 (40.7)	10 (6.2)	62 (38.3)	162 (100)	

Canal length of maxillary and mandibular molars

A total of 585 molars were measured, and the results for canal length are shown in Table 6. The mean length of the palatal canal for the maxillary first molar was 20.62 mm, and for the maxillary second molar it was 18.86 mm. The mean value of the mesiobuccal canal length was 19.30 mm among first maxillary molars and 20.09 mm among second maxillary molars. The average length of the distobuccal canal was 19.08 mm among first maxillary molars, and 19.11 mm among maxillary second molars.

Mesial root canals of mandibular molars had the average length of 20.72 mm for the first molar, and 20.06 mm for the second molar. The distal root canal of mandibular molars had an average length of 20.05 mm among first

mandibular molars, and 19.64 mm among second mandibular molars.

The differences in canal lengths were compared between sexes and jaw side. For the maxillary first molar, there was a statistically significant difference in relations to sex – the palatal, mesiobuccal and distobuccal canals of the maxillary first molar were found to be longer in the males. Among second maxillary molars, a statistically significant difference ($p=0.021$) was found in the length of the distobuccal canal, which was longer in men. In relation to the jaw side, there was a statistically significant difference in mesiobuccal ($p=0.035$) and palatal canal ($p=0.045$). The mean lengths of the mesiobuccal and palatal canal were higher on the left side of the jaw. The difference in mean length of distobuccal root canals according to sex was

statistically significant ($p = 0.021$). The difference was significant for mesial root canal of the first mandibular molar relative to the side ($p = 0.034$). For the mandibular second

molar, statistical significance was found for both mesial and distal canal according to sex.

Table 6**Root canal lengths of maxillary and mandibular molar roots according to sex and jaw side**

Tooth	Range, mm		Mean (SD), mm		<i>p</i>	Mean (SD), mm			<i>p</i>
	min.	max.	male	female		right side	left side	Total	
Maxillary first molar									
Root									
mesiobuccal	16.18	23.41	19.67(1.34)	18.72(1.24)	< 0.001*	18.84(1.34)	19.45(1.38)	19.30 (1.42)	0.035*
distobuccal	14.24	21.69	19.26(1.47)	18.52(1.60)	0.012*	18.72(1.91)	18.99(1.17)	19.08 (1.59)	0.941
palatal	18.02	22.72	20.93 (0.93)	20.20(1.03)	< 0.001*	20.30(1.14)	20.75(0.90)	20.62 (1.04)	0.045*
Maxillary second molar									
Root									
mesiobuccal	16.13	25.11	19.25 (1.52)	19.06(1.42)	0.379	19.06(1.42)	19.21(1.51)	20.09(1.37)	0.642
distobuccal	15.71	23.25	18.89(1.32)	18.54(1.42)	0.021*	18.71(1.48)	18.73(1.31)	19.11(1.44)	0.472
palatal	16.10	23.16	20.18(1.64)	19.76(1.04)	0.060	19.77(1.37)	20.11(1.42)	18.86(1.27)	0.071
Mandibular first molar									
Root									
mesial	17.89	25.50	20.73(1.81)	20.72(1.42)	0.763	20.76(1.49)	20.69(1.73)	20.72(1.61)	0.643
distal	17.57	23.40	19.96(1.63)	20.16(1.04)	0.182	20.35(1.48)	19.77(1.18)	20.05(1.36)	0.034*
Mandibular second molar									
Root									
mesial	17.23	23.78	20.47(1.62)	19.44(0.91)	< 0.001*	20.16(1.54)	19.95(1.38)	20.06(1.46)	0.585
distal	17.20	23.63	19.98(1.44)	19.11(1.04)	< 0.001*	19.69(1.55)	19.58(1.14)	19.64(1.37)	0.906

SD – standard deviation; *Statistically significant difference using the Mann-Whitney *U*-test.

Discussion

In Europe, CBCT, as a radiographic technique designed specifically for hard tissues of the maxillofacial region was introduced in dental practice in 1998¹⁵. Today, it is most commonly used in the fields of oral surgery, implantology, and orthodontics, but also in the field of endodontics for a three-dimensional analysis of the external and internal tooth morphology¹². Other than CBCT, a variety of different techniques are used to analyze the root and root canal morphology such as classical radiography, an electronic microscope, micro-CT and cleaning and staining technique, which is considered the gold standard. In the terms of the precision, CBCT shows the same level as cleaning and staining technique¹⁶. CBCT provides high precision, minimal distortion and 3-dimensional (3D) image projection⁸.

Among maxillary first molars, we obtained the highest prevalence of three roots and a small percentage of single rooted first molars (0.7%) as reported by other studies^{2, 5, 8, 17, 18}. The diversity of root numbers in maxillary first molars was not found. The Alrahabi et al.¹⁹ showed a slightly smaller percentage of molars with three roots, while Barbizam et al.²⁰ showed molars with four and five roots in their population, but still in a very small percentage.

Canal configuration of palatal root showed no variations, with one canal in all cases, as shown by other studies in diverse populations^{8, 11, 18, 19}. In the distobuccal root, Vertucci type I was the most prevalent with a scarce variation in canal morphology. Similar results were shown by Ghoncheh et al.¹⁸ for Iranian population (97.33%), as well as others^{2, 8, 11, 19, 21}.

Unlike palatal and distobuccal, the mesiobuccal root showed diversity in the number of canals and canal morphology. In our study, two mesiobuccal canals were present in more than half of the examined first molars, with Vertucci type II as the most frequent (28.98%). Previous studies have also shown the highest percentage of two mesiobuccal canals^{2, 8, 11, 22, 23}. Vertucci type II, as the most prevalent complex configuration, was shown in a study of Ratanajirasut et al.⁸ (28.98%) for Thai population and, with a slightly lower percentage (23.2%), in a study of Pérez-Heredia et al.²⁴ for Spanish population. Vertucci type III and type IV followed with the same frequency (8.69%). Approximate results for type IV were shown in a study conducted in Turkey²⁵, while studies conducted in India and Korea^{23, 26} reported type IV in a much larger percentage (40.65% and 38.6%, respectively). We demonstrated higher frequency of two mesiobuccal canals in males than females. These results were in accordance with our previous study of premolar teeth¹⁴. For maxillary molars, our results were similar to findings in Thai population,⁸ where 70.9% of males had complex canal configurations.

Unlike the maxillary first molar, the second molars showed a slightly higher diversity in the number of roots. In our study, most maxillary second molars had three roots (90.4%), as in a study of Ratanajirasut et al.⁸ for Thai population (78.1%) and other studies^{18, 23, 24, 26}. Two roots were much less frequent (5.4%), which coincides with the results for Iranian and Indian populations^{18, 26}. Single-rooted maxillary second molars were considerably less frequent, but the recorded percentage was higher compared with first molars. Similar results were found for different populations in other studies^{8, 18, 23, 24, 26}.

All the palatal and distobuccal roots of maxillary second molars presented Vertucci type I configuration. These findings are consistent with previous results for Thai⁸, Korean²³ and Spanish population²⁴. More diversity in root canal configurations was found for Iranian and Indian populations^{18,26}, which can be attributed to our study sample size.

In the mesiobuccal root of maxillary second molars, two canals were present in 39.5%. The most frequent was the Vertucci type I configuration as previously reported^{8,18,23,24,26}. Our study indicated that the second molars had most frequently Vertucci type II, which is similar to a study in European population²⁴ and several studies conducted in Asia^{8,23}. Other studies of Asian population, made by Ghoncheh et al.¹⁸ and Neelakantan et al.²⁶ showed the second highest prevalence of Vertucci type IV. In our study type IV was presented as the third most frequent. These differences could be due to population's ethnical origin or a result of different sample's size. Our findings presented Vertucci type VII in 2 cases, but no cases with type VI or VIII, unlike previous studies^{8,18,23,24,26}.

These results could be attributed to a difficulty to differentiate types with such complexity. Unlike in first molars, results for prevalence of two mesiobuccal canals in the maxillary second molar showed no statistical difference between sexes, although it was noticeable that two root canals were more frequent in males. Identical results were shown previously^{8,23}.

Previous studies have shown that the first mandibular molars have two roots, predominantly. A study in the white population² showed that all analyzed molars had two roots, as presented in the study we conducted. Similar results were found in studies conducted in Spain²⁴, and Belgium and Chile²⁷, while studies conducted in Korea⁵ and Thailand²⁸ showed a lower percentage of two roots (87.3% and 73.5%, respectively).

As expected, the distal root presented a simpler root canal morphology than mesial. Vertucci type I was the most frequent, which coincides with the results of studies conducted in Spain and Belgium^{24,27}. Vertucci types II and III were found in a low percentage, as in other studies^{5,24,29}.

Unlike distal root of mandibular molars, the mesial root presents a challenge in endodontic therapy. Our findings showed that in most cases, the mesial root had two canals, with the highest frequency of Vertucci type IV, which was confirmed in a study on white population², but also on populations of Thailand⁵, Burma¹⁰ and Uganda²⁹. Vertucci type II was the second most frequent in our population, which was also reported for diverse populations^{2,5,24,29}. Unlike in our population, where the frequency of type III and type V was quite low, a study conducted in Chile and Belgium showed the opposite²⁷.

The mandibular second molar did not show large variations in root numbers, with two-rooted molars mostly presented, which was previously reported as well^{2,24,27}. The number of canals in mesial root showed similarity to mandibular first molar, while distal root was presented with one root canal in almost all cases. Previous reports showed similar results^{2,10,25,27,29}.

Our findings showed Vertucci type II to be the most common finding in the mesial root, followed by type IV. Studies conducted in Thailand⁵, Burma¹⁰ and Uganda²⁹ showed the highest frequency of Vertucci type IV. Unlike our findings for mandibular first molar, a low frequency of Vertucci type III was presented for the second molar. Contrary to ours, populations of Belgium and Chile showed a higher prevalence of this type²⁹.

Our findings did not show any statistical differences in canal complexity between sexes for both mandibular molars. Lack of sex differences was previously reported by Kim et al.²⁸.

Besides knowledge of the root canal morphology and the number of roots, for the success of endodontic therapy, knowledge of adequate canal root length is also required. CBCT has found its application in endodontics in the analysis of canal morphology and finding an unexpected number of canals, and gradually it finds application in measuring the length of the root canal as well. For example, in North Korea, the most common non-surgical procedure for which CBCT is used, is measuring the length of the canal. A 3D approach in measuring the length of the root canal has shown to give little variations (0.22–0.42 mm) from the actual canal length⁶. Liang et al.³⁰ assessed CBCT validity in the measurement of canal length compared to the gold standard, electro-odontometry. They showed that the absolute difference between these two methods was ranging from 0.44 to 0.59 mm, and stated that the difficulty to determine the working length of the molar canals due to the large curvature of the roots must be considered³⁰. It may not be necessary to use CBCT only for determining the length of the root canal, but if patients have a CBCT image for some other indication, we might have a possibility to get an insight into the expected working lengths. Surely, in combination with electro-odontometry, in everyday practice, we can increase the accuracy of the measured working length and success of endodontic treatment.

According to our knowledge, there are not many studies dealing with this topic, but for example, in the study of Rodríguez-Niklitschek et al.³¹ the length of the second maxillary and mandibular molars were measured by the electro-odontometry method. The average lengths of mesiobuccal and distobuccal canals of the second maxillary molars were similar to those in our study, except for the mean length of the palatal canal that was smaller in our population than in Chile³¹. In the Chilean study, there was no statistically significant difference according to sex, opposed to our study where we found that distal canals were longer in males. The average length of the canals of the second mandibular molars in our population was similar to those in the study of Rodríguez-Niklitschek et al.³¹ root canals were significantly longer in male subjects in both studies.

To our knowledge, side asymmetry in tooth lengths, and possible causes of such a finding had not been previously reported. Keles et al.³² demonstrated asymmetries in the facial area and stated that differences were related to handedness, where right-handed persons had larger left facial area compared to left-handed and *vice versa*. Our study lacks in data regarding handedness.

Conclusion

The results of this study founded that three roots were the most frequent in both maxillary first and second molars, while the canal morphology was different. The two mesio-buccal canals of the maxillary first molar were present in more than half of the examined teeth, while the frequency was lower for the maxillary second molar. As expected, palatal and distobuccal roots did not have complex canal morphology, contrary to mesiobuccal root canal. Mandibular molars also did not show big variations in the number of roots – two roots were most frequently present in both molars. The distal root had simple canal morphology with one root canal in the majority of cases. Also, the mesial roots of both molars showed two canals in the most of cases, but the frequency of Vertucci types were different – type IV was

most frequently present in the mesial root of the mandibular first molar, while in the second molar, type II was most frequently present.

The palatal canal was the longest in maxillary first molars, followed by mesiobuccal and distobuccal root canals. Mesial canals of mandibular molars were longer than distal root canals. The mean root canal lengths in both maxillary and mandibular molars were bigger in males.

In relation to the jaw side, there was a statistically significant difference in the length of the mesiobuccal and palatal root canals, which were found to be longer on the left side of the jaw. The results of our study showed, that the attention should be paid during endodontic treatment because there are differences not only in root canal morphology, but also in the length of the root canals between populations, sexes and side of the jaw.

R E F E R E N C E S

1. Vertucci FJ. Root canal anatomy of the human permanent teeth. *Oral Surg Oral Med Oral Pathol* 1984; 58(5): 589–99.
2. Plotino G, Tucci L, Grande NM, Testarelli L, Messineo D, Ciotti M, et al. Symmetry of root and root canal morphology of maxillary and mandibular molars in a white population: a cone-beam computed tomography study in vivo. *J Endod* 2013; 39(12): 1545–8.
3. Beljić-Ivanović K, Teodorović N. Morphological characteristics of mesiobuccal root canals of the first maxillary molars. *Srp Arh Celok Lek* 2010; 138(7–8): 414–9. (Serbian)
4. Gulabivala K, Opananon A, Ng YL, Alavi A. Root and canal morphology of Thai mandibular molars. *Int Endod J* 2002; 35(1): 56–62.
5. Tchorz JP, Poxleitner PJ, Stampf S, Patzelt SBM, Rottke D, Hellwig E, et al. The use of cone beam computed tomography to predetermine root canal lengths in molar teeth: a comparison between two-dimensional and three-dimensional measurements. *Clin Oral Investig* 2014; 18(4): 1129–33.
6. Jeger FB, Janner SF, Bornstein MM, Lussi A. Endodontic working length measurement with preexisting cone-beam computed tomography scanning: a prospective, controlled clinical study. *J Endod* 2012; 38(7): 884–8.
7. de Pablo OV, Estevez R, Péix Sánchez M, Heilborn C, Cobenca N. Root anatomy and canal configuration of the permanent mandibular first molar: a systematic review. *J Endod* 2010; 36(12): 1919–31.
8. Ratanajirasut R, Panichuttra A, Panmekiate S. A Cone-beam Computed Tomographic Study of Root and Canal Morphology of Maxillary First and Second Permanent Molars in a Thai Population. *J Endod* 2018; 44(1): 56–61.
9. Clegborn BM, Christie WH, Dong CC. Root and root canal morphology of the human permanent maxillary first molar: a literature review. *J Endod* 2006; 32(9): 813–21.
10. Gulabivala K, Aung TH, Alavi A, Ng YL. Root and canal morphology of Burmese mandibular molars. *Int Endod J* 2001; 34(5): 359–70.
11. Rajan Dhavan M, Dhavan S, Mehta P. Analysis of Root Canal Anatomy & Morphological Variations of Maxillary 1st Molar by Different Methods - An In Vitro Study. *Endodontology* 2014; 26(2): 279–85.
12. de Toubes KM, Côrtes MI, Valadares MA, Fonseca LC, Nunes E, Silveira FF. Comparative analysis of accessory mesial canal identification in mandibular first molars by using four different diagnostic methods. *J Endod* 2012; 38(4): 436–41.
13. Popović M, Papić M, Živanović S, Acović A, Lončarević S, Ristić V. Cone-beam computed tomography study of root canal morphology of mandibular anterior teeth in Serbian population. *SJECR Serb Exp Clin Res* 2018; 19(1): 27–34.
14. Popović M, Papić M, Acović A, Živanović S, Kanjevac T. Cone-beam Computed Tomography Study of Root Number and Root Canal Configuration of Premolar Teeth in Serbian population. *Med Pregl* 2018; 71(3–4): 100–7.
15. Hatcher DC. Operational principles for cone-beam computed tomography. *J Am Dent Assoc* 2010; 141 Suppl 3: 3S–6S.
16. Nikolić M, Mitić A, Gašić J, Popović J, Barac R, Dačić S, et al. First premolar variations in number of roots, root canals and tooth length. *Glasnik Antropološkog Društva Srbije* 2014; 2014(49): 37–41.
17. Thomas RP, Moule A, Bryant R. Root canal morphology of maxillary permanent first molar teeth at various ages. *Int Endod J* 1993; 26(5): 257–67.
18. Ghoncheh Z, Zade BM, Kharazmjard MJ. Root Morphology of the Maxillary First and Second Molars in an Iranian Population Using Cone Beam Computed Tomography. *J Dent (Tehran)* 2017; 14(3): 115–22.
19. Alrababi M, Sobail Zafar M. Evaluation of root canal morphology of maxillary molars using cone beam computed tomography. *Pak J Med Sci* 2015; 31(2): 426–30.
20. Barbizam JV, Ribeiro RG, Tanomaru Filho M. Unusual anatomy of permanent maxillary molars. *J Endod* 2004; 30(9): 668–71.
21. Özcan G, Sekerci AE, Cantekin K, Aydinbelge M, Dogan S. Evaluation of root canal morphology of human primary molars by using CBCT and comprehensive review of the literature. *Acta Odontol Scand* 2016; 74(4): 250–8.
22. Wolcott J, Isbley D, Kennedy W, Johnson S, Minnich S. Clinical investigation of second mesiobuccal canals in endodontically treated and retreated maxillary molars. *J Endod* 2002; 28(6): 477–9.
23. Kim Y, Lee SJ, Woo J. Morphology of maxillary first and second molars analyzed by cone-beam computed tomography in a Korean population: variations in the number of roots and canals and the incidence of fusion. *J Endod* 2012; 38(8): 1063–8.
24. Pérez-Heredia M, Ferrer-Luque CM, Bravo M, Castelo-Baz P, Ruiz-Piñón M, Baca P. Cone-beam Computed Tomographic Study of Root Anatomy and Canal Configuration of Molars in a Spanish Population. *J Endod* 2017; 43(9): 1511–6.

25. Sert S, Aslanalp V, Tanalp J. Investigation of the root canal configurations of mandibular permanent teeth in the Turkish population. *Int Endod J* 2004; 37(7): 494–9.
26. Neelakantan P, Subbarao C, Abuja R, Subbarao CV, Gutman JJ. Cone-Beam Computed Tomography Study of Root and Canal Morphology of Maxillary First and Second Molar in an Indian Population. *J Endod* 2010; 36(10): 1622–7.
27. Torres A, Jacobs R, Lambrechts P, Brizuela C, Cabrera C, Concha G, et al. Characterization of mandibular molar root and canal morphology using cone beam computed tomography and its variability in Belgian and Chilean population samples. *Imaging Sci Dent* 2015; 45(2): 95–101.
28. Kim SY, Kim BS, Woo J, Kim Y. Morphology of mandibular first molars analyzed by cone-beam computed tomography in a Korean population: variations in the number of roots and canals. *J Endod* 2013; 39(12): 1516–21.
29. Rwenyonyi CM, Kutesa A, Munwazi LM, Buwembo W. Root and canal morphology of mandibular first and second permanent molar teeth in a Ugandan population. *Odontology* 2009; 97(2): 92–6.
30. Liang YH, Jiang L, Chen C, Gao XJ, Wesselink PR, Wu MK, et al. The validity of cone-beam computed tomography in measuring root canal length using a gold standard. *J Endod* 2013; 39(12): 1607–10.
31. Rodríguez-Niklitschek C, Cantín M, Oporto VG. Comparison of Two Different Methods of Average Working Length Determination in Second Molars and Premolars. *Int J Morphol* [online] 2015; 33(3): 1136–40.
32. Keleş P, Dýyarbakirli S, Tan M, Tan U. Facial asymmetry in right- and left-handed men and women. *Int J Neurosci* 1997; 91(3–4): 147–59.

Received on May 23, 2018.

Revised on April 18, 2018.

Accepted on May 16, 2018.

Online First May, 2018.